

*Patientendag SAB*

SPAR in samenwerking met  
Radboudumc

01-11-2025

---

Prof. Dr. Jeroen Boogaarts  
Neurochirurg

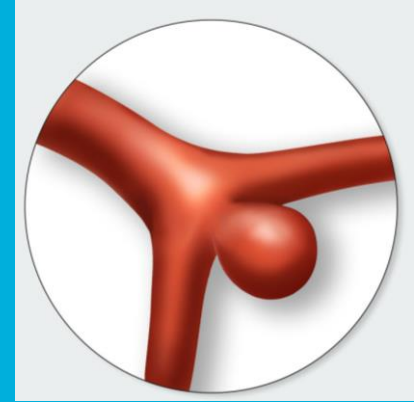
**Radboudumc**  
university medical center

---

# WELKOM !

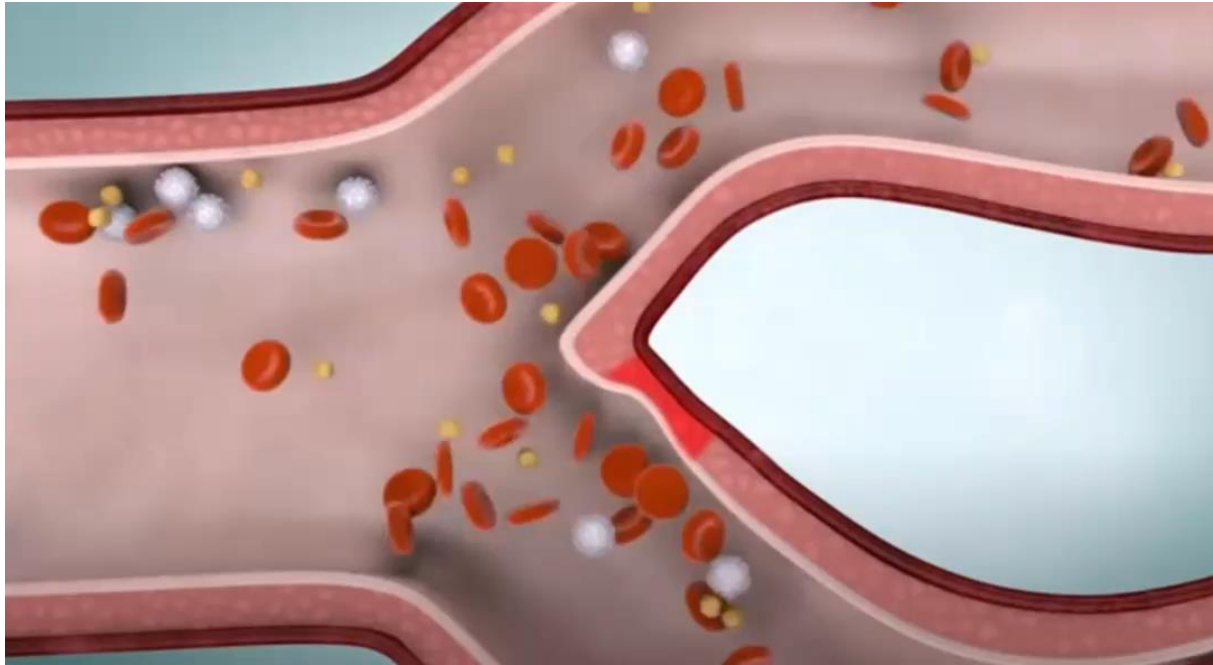


# Aneurysma



---

# Aneurysma

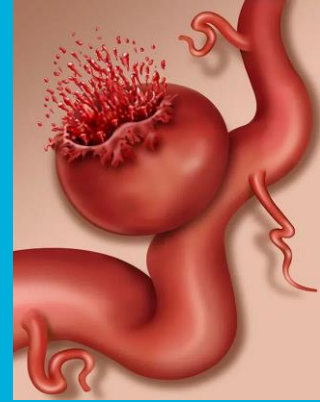

---

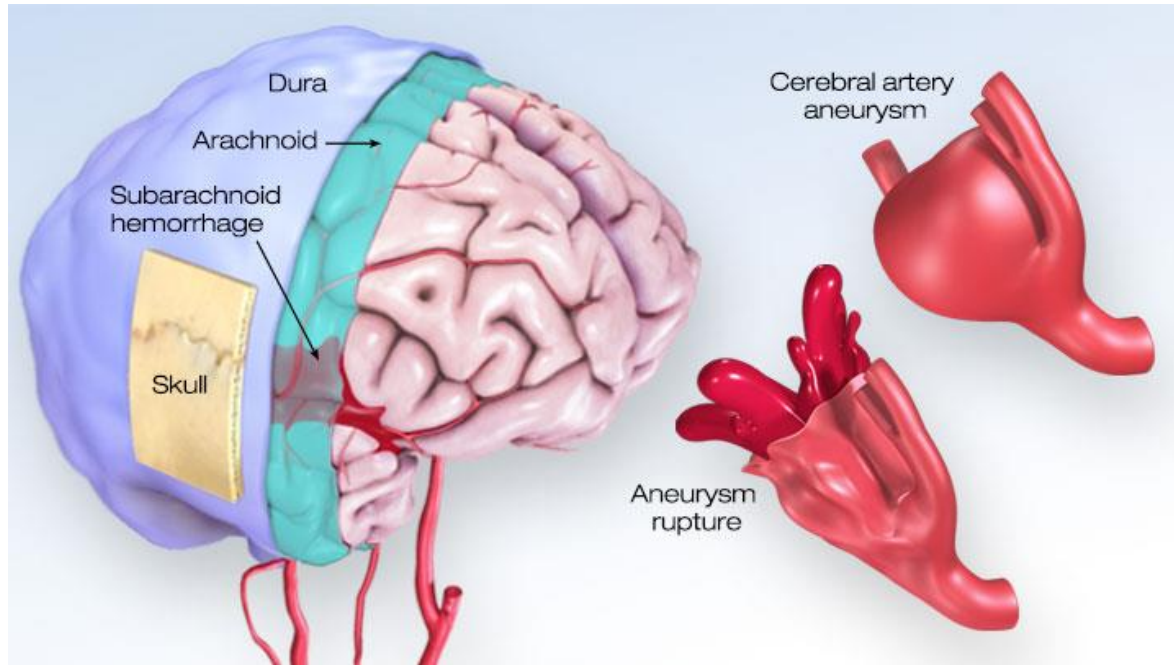
# Aneurysma - risicofactoren



# Subarchnoïdale bloeding

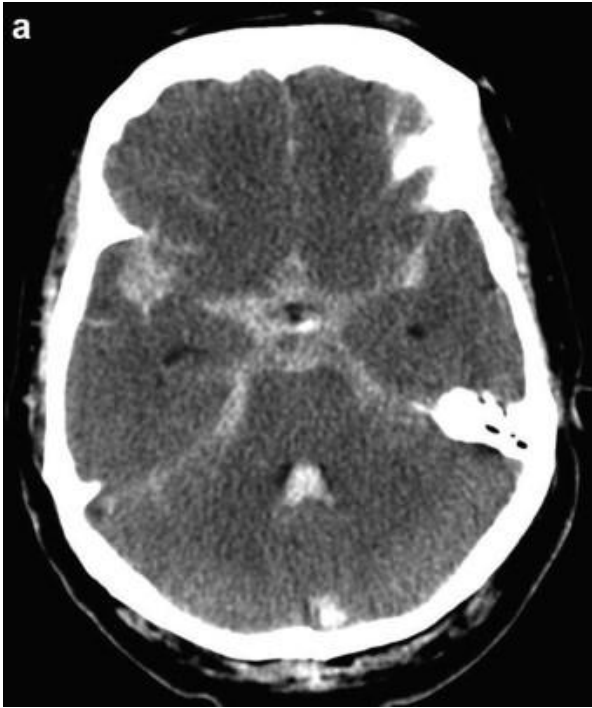

# Subarchnoïdale bloeding



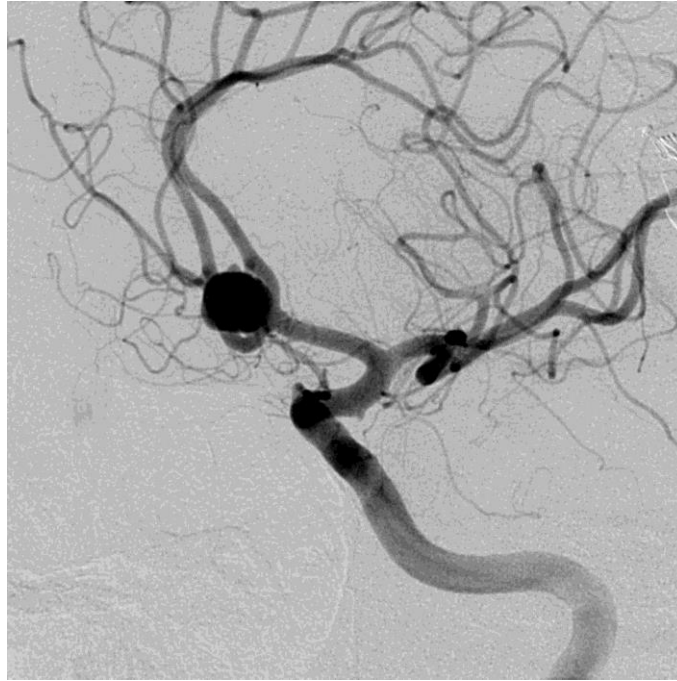
---

# SAB – diagnose - beeldvorming



---

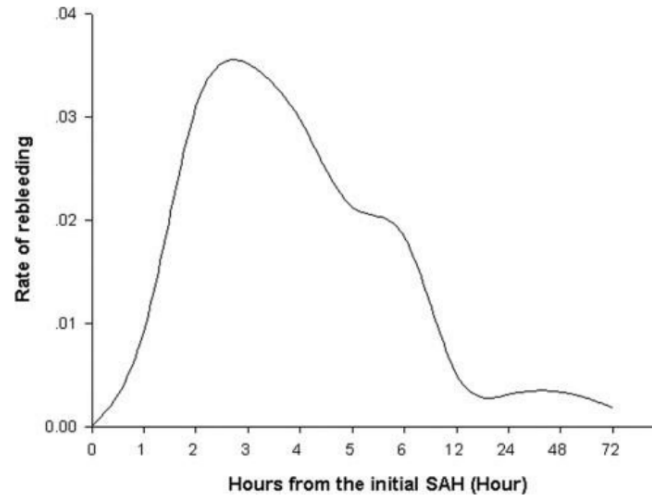
# DSA



---

# Complicaties - rebleed

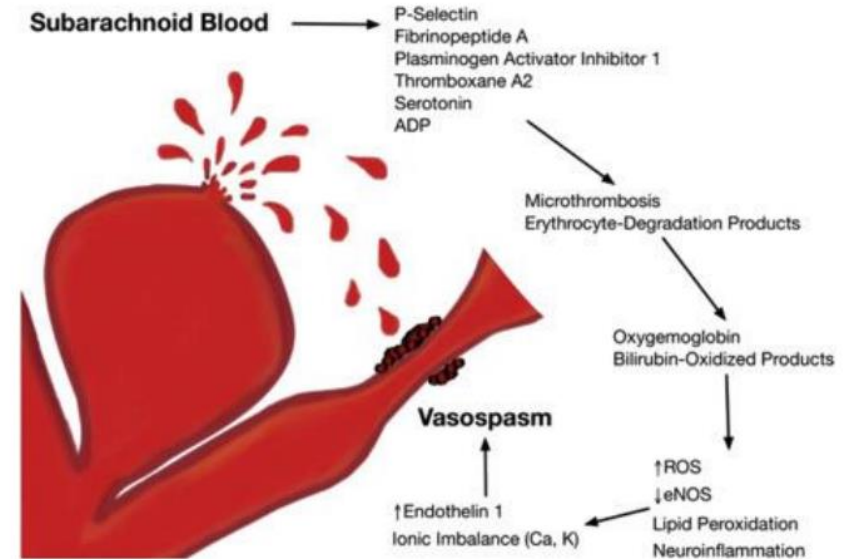
rebleed: time



Guo, 2012

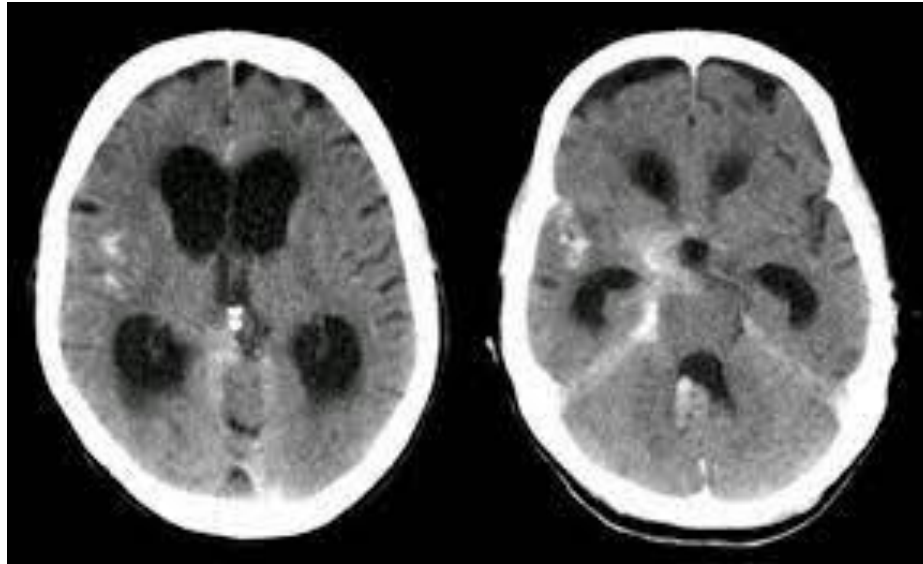
# Complicaties DCI

- Delayed cerebral ischemia
- (Vaatspasmen)
- 2 punten EMV daling/  
focale uitval
- Verdubbeling op risico  
op slechte uitkomst
- Geen bewezen zinvolle therapie

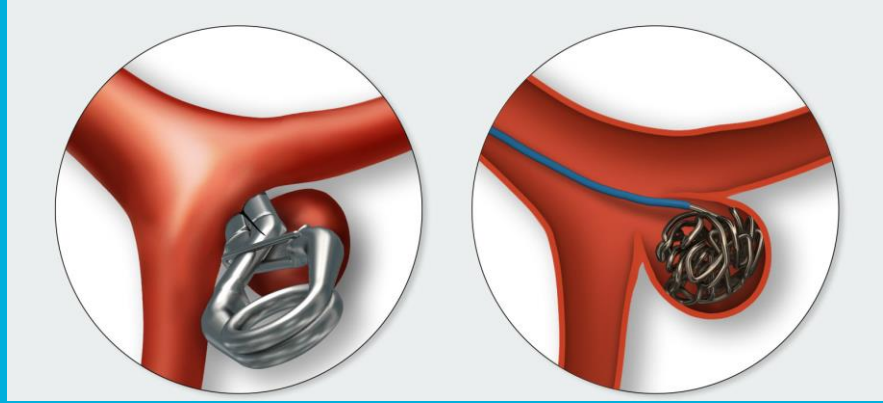


---

# Complicaties - Hydrocephalus

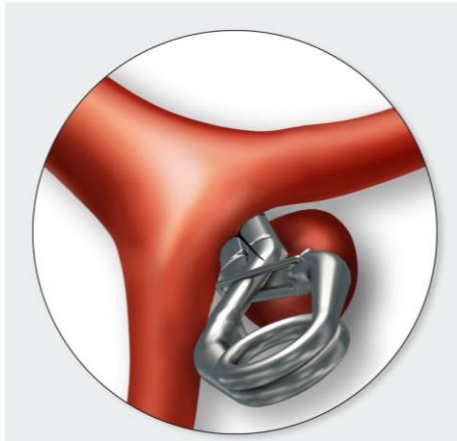


# Behandeling

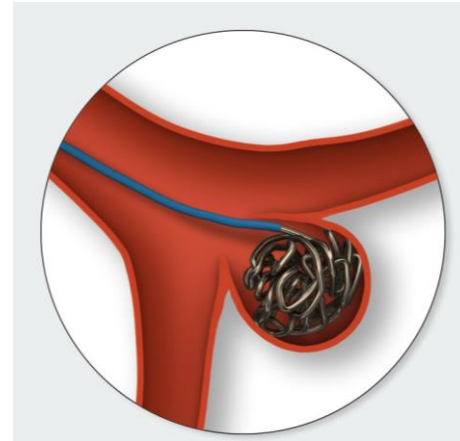

---

# Hoe behandel je?



Open chirurgisch

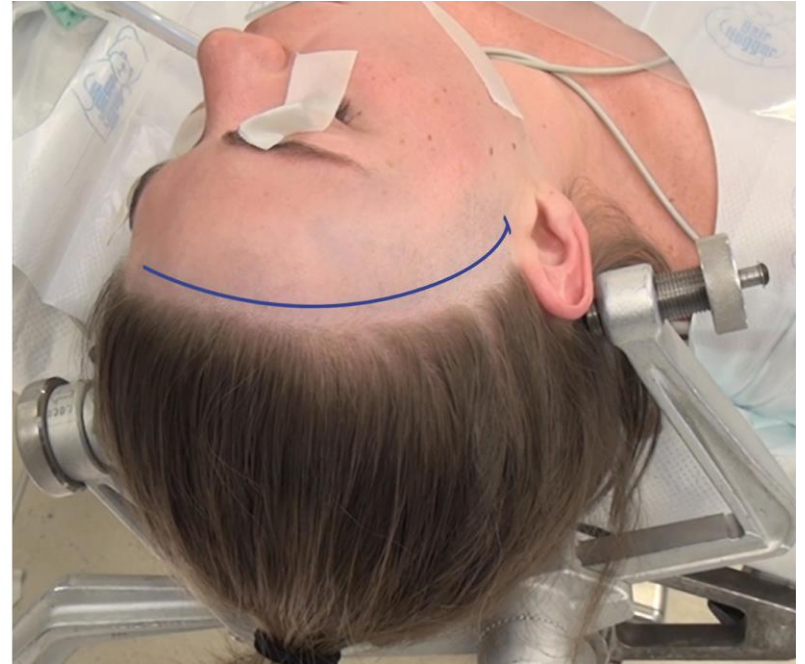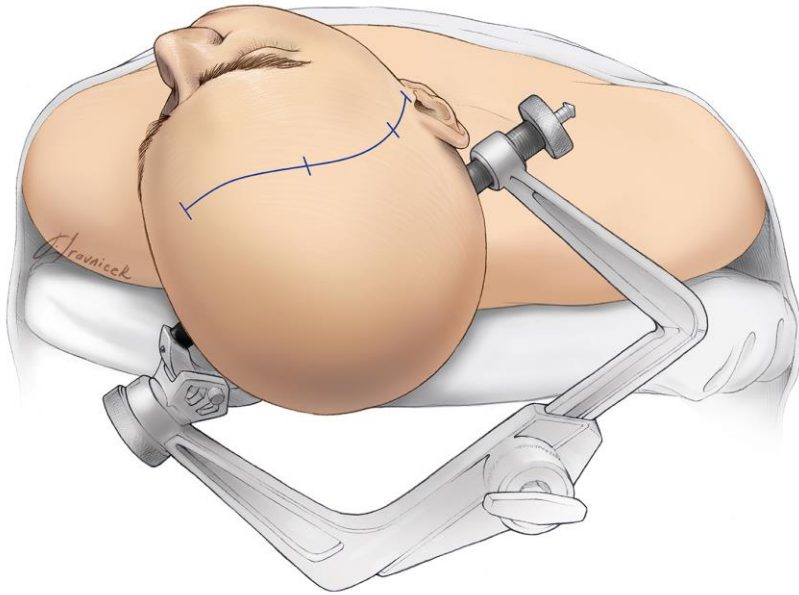


Endovasculair

Hybride

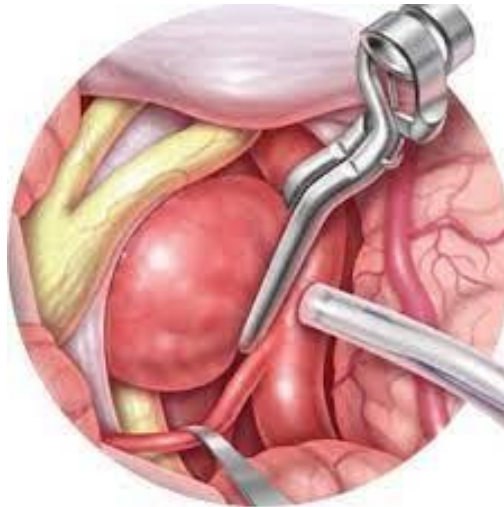---

# Open chirurgisch

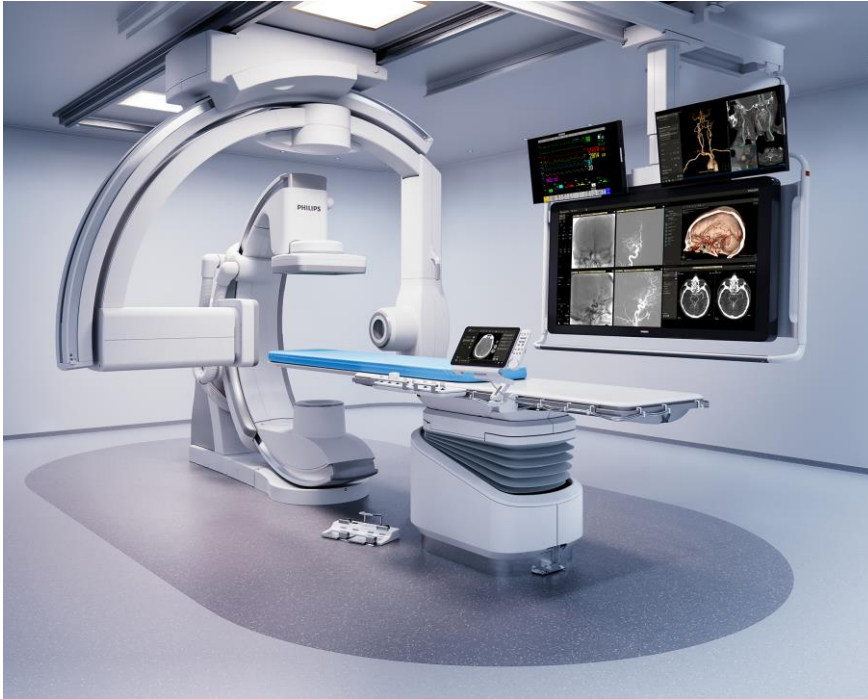


---

# Controle - Doppler

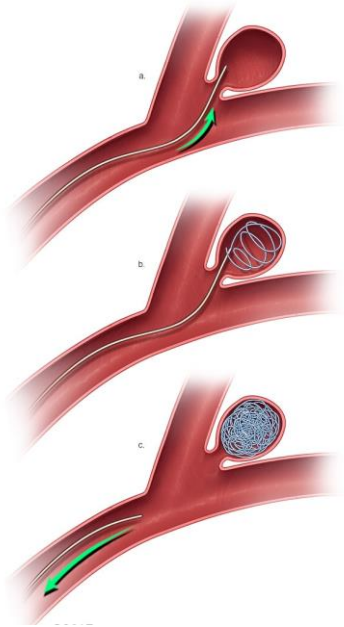


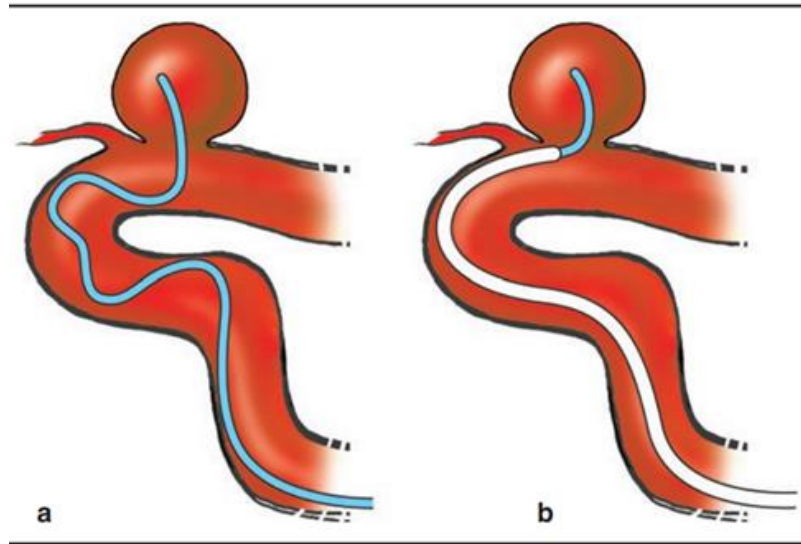
# Endovasculair

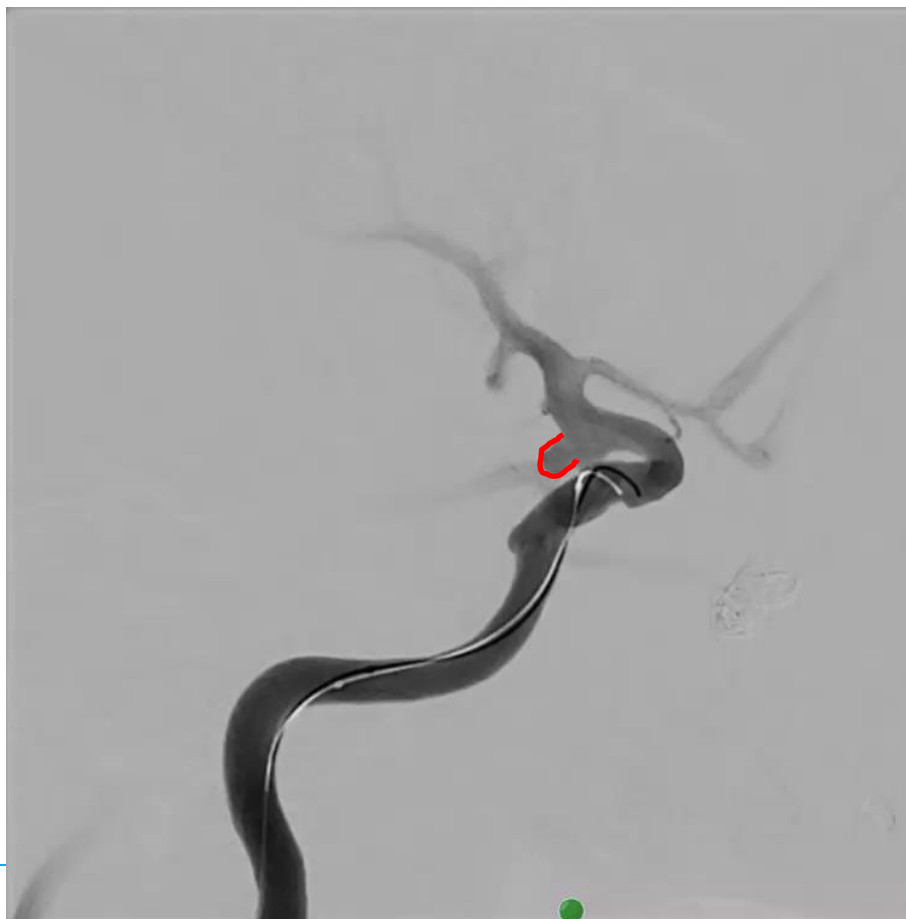

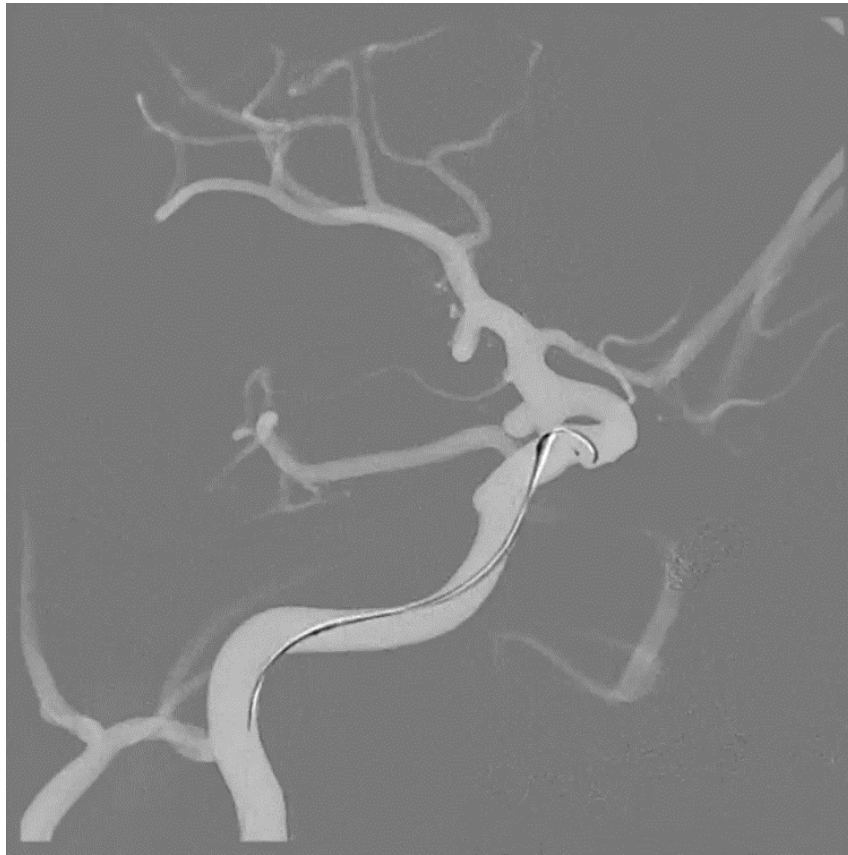---

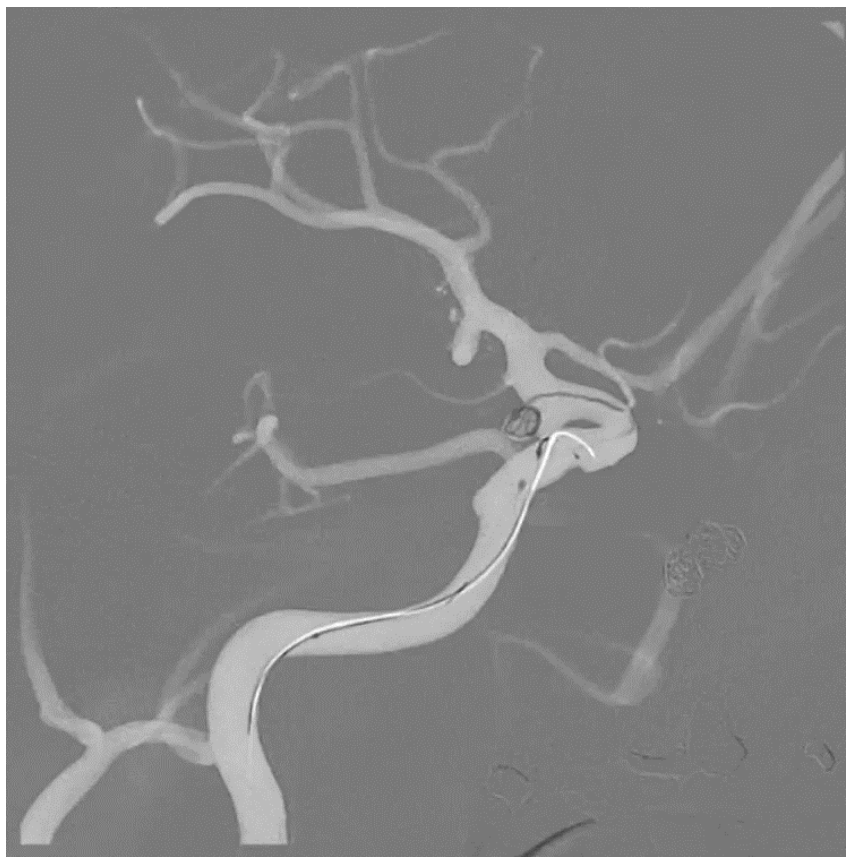
# Endovasculair - coiling

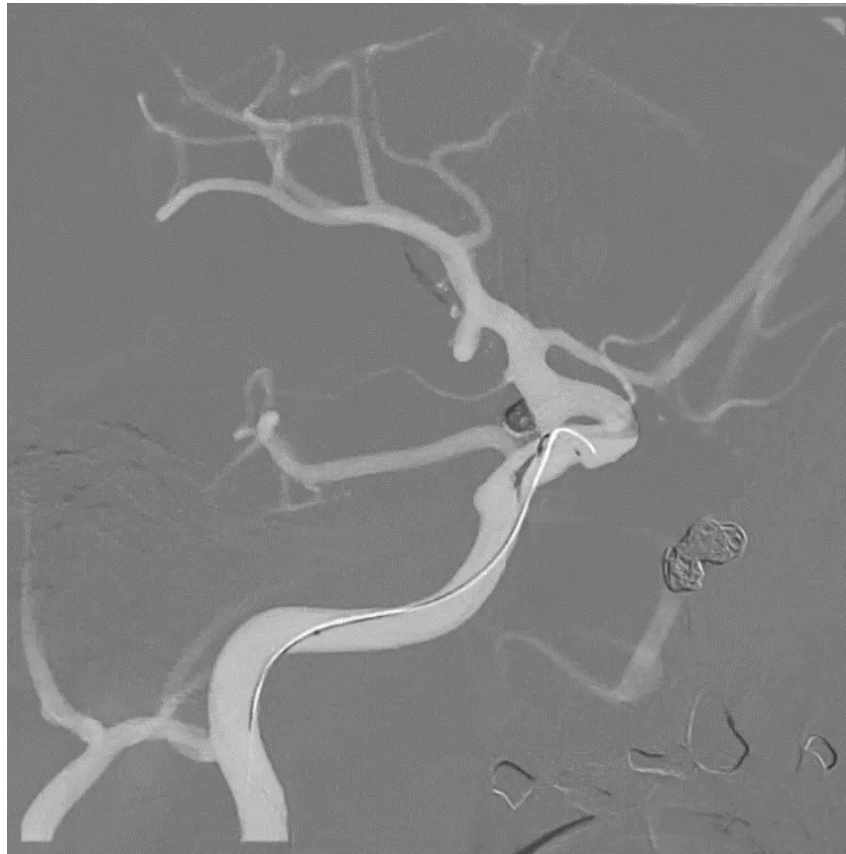




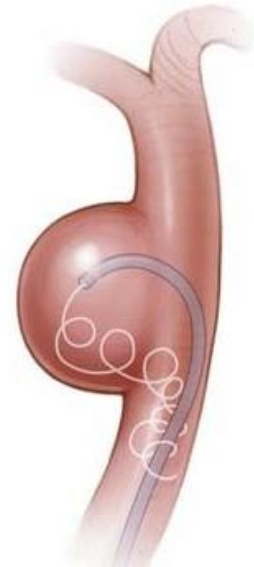
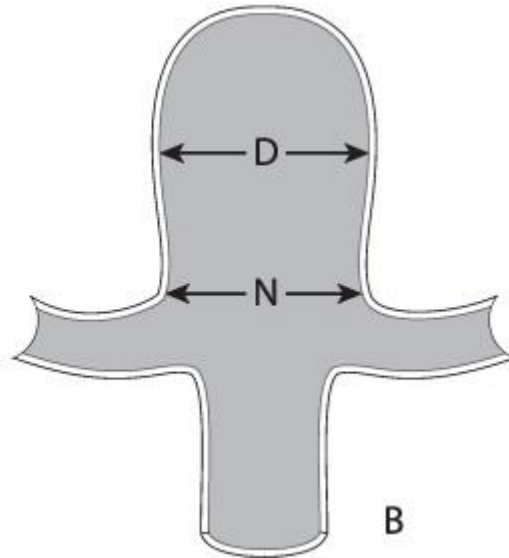
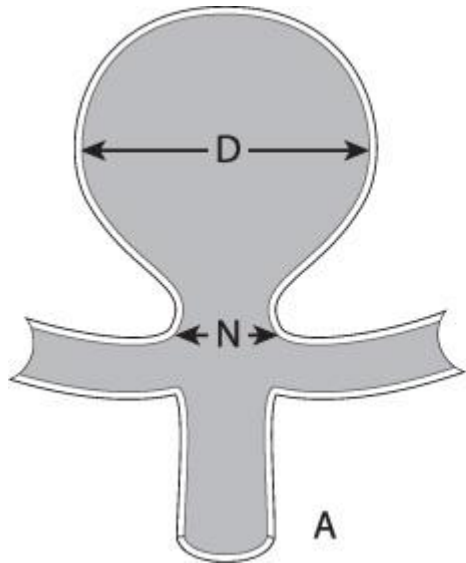






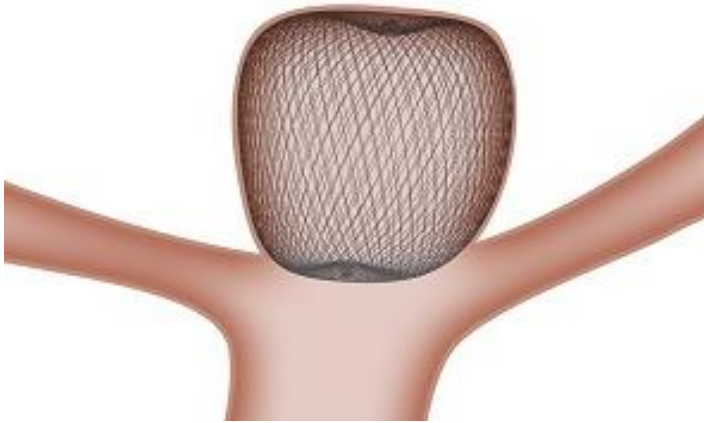

# Niet elk aneurysma is coilbaar

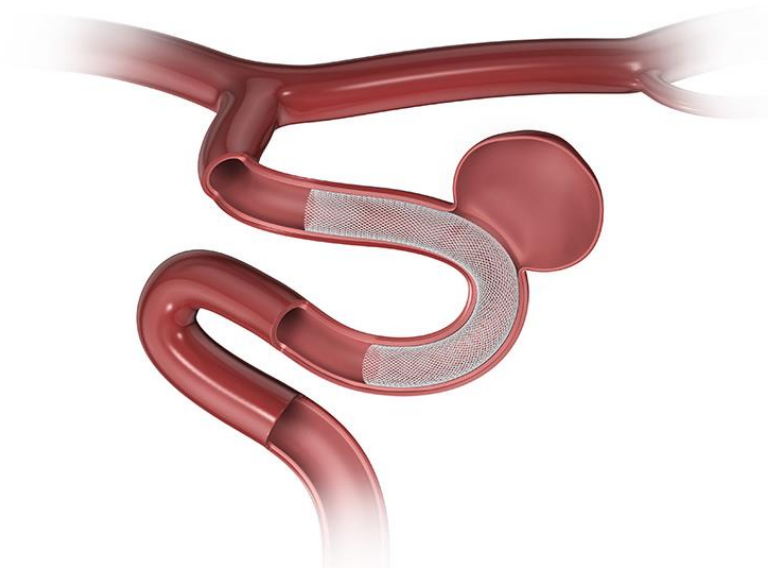

---

# Endovasculair - alternatieven

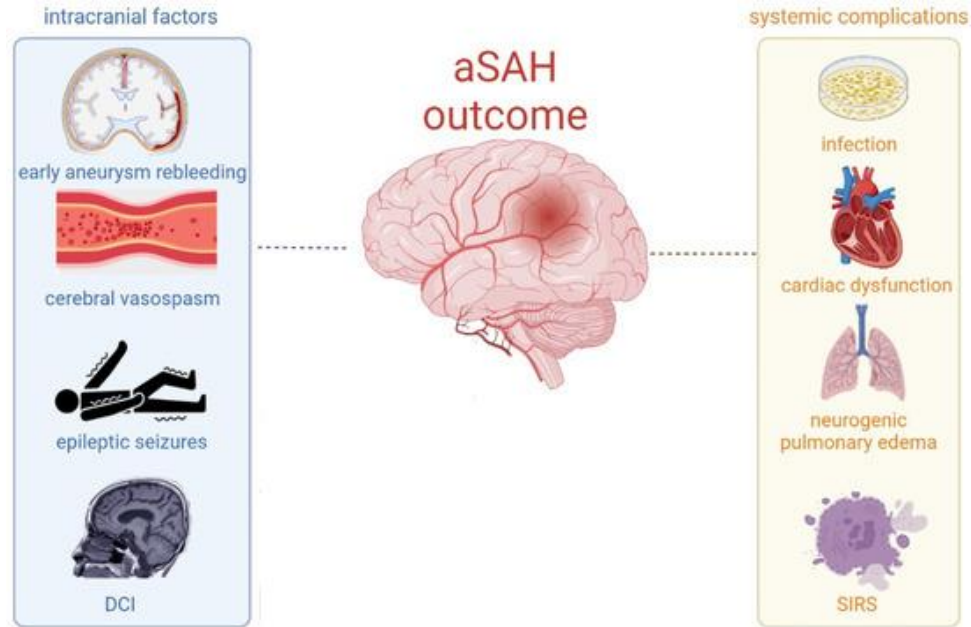


WEB



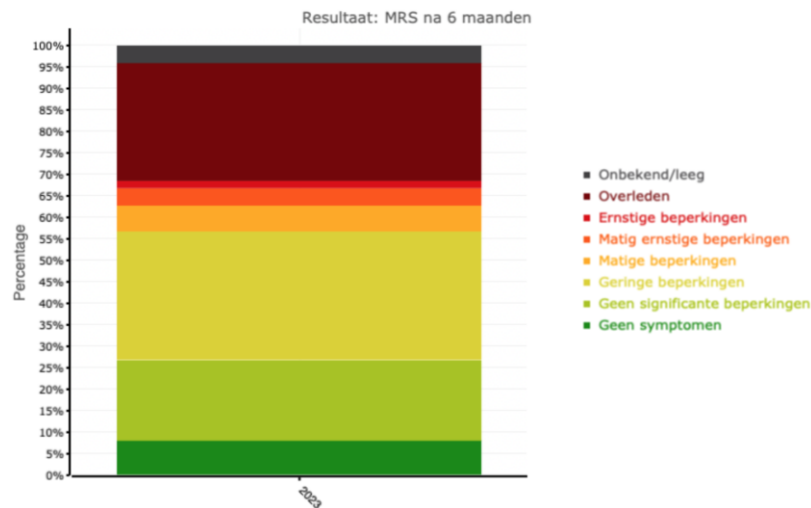
FLOW diverter

# Uitkomst



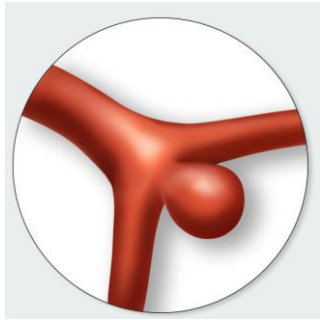
# Uitkomst

- 35% overlijdt binnen drie maanden
- Een derde kan zelfstandig functioneren
  - 50% werkhervatting

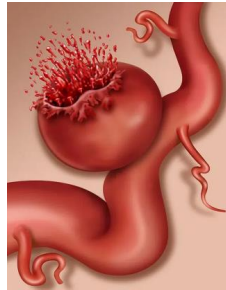

---

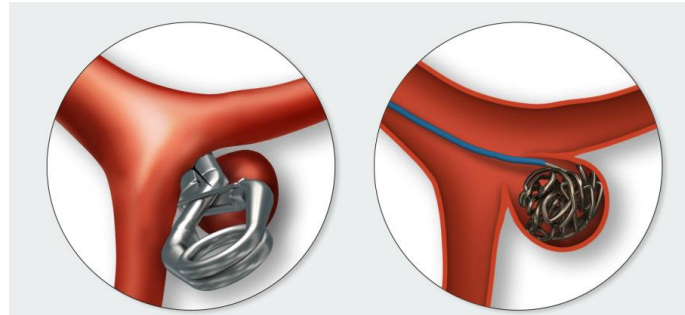
# Conclusie



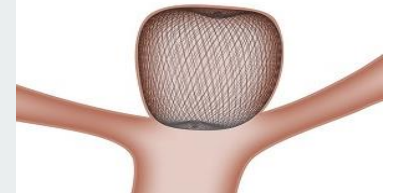Aneurysma



SAB



Behandeling



WEB

---

# Dank voor jullie aandacht

